

## Place For Percutaneous Nephrolithotomy In Contemporary Era.

Abdul Majid Rana<sup>1</sup>

<sup>1</sup>-*Department of Urologist Institute of Medicine and Surgery.Dow University of Health Sciences Karachi, Pakistan*

### ABSTRACT

The basic surgical options for big (>20 mm) stag horn and diseased stones are often regarded as percutaneous nephrolithotomy (PCNL) and its miniaturized variations. Furthermore, in cases where lower pole stones are unreachable, or there are anatomical anomalies, PCNL is a good substitute for retrograde intracranial surgery (RIRS) for smaller stones (<20 mm). However, RIRS is extending its indications with the potential advantages of fewer problems and a shorter hospital stay, thanks to advancements in stone fragmentation devices and optical technology. Current research publications attest to the importance of this process and its possible use in managing big and complicated stones. However, miniaturized PCNL has grown more competitive and is starting to take place among the traditional signs of flexible ureteroscopy. Considering every recent advancement made in executing this process, PCNL is unquestionably a tried-and-true method that will continue to be at the forefront of technology for some time.

**Keywords:** Percutaneous Nephrolithotomy, Kidney Stones, Urological Surgery

**How to Cite:** Rana AM. Place For Percutaneous Nephrolithotomy In Contemporary Era: Review Article. **Pakistan J Urol.** 2023;1(01):01-06. [doi:10.69885/pju.v1i01.14](https://doi.org/10.69885/pju.v1i01.14).

**Corresponding Author:** Abdul Majid Rana

**Email:** [rana\\_abdumajid@hotmail.com](mailto:rana_abdumajid@hotmail.com)

Department of Urologist Institute of Medicine and Surgery.Dow University of Health Sciences Karachi, Pakistan

<https://orcid.org/0000-0003-0956-0234>

**Cell No: + 92-310 5312122**

### Article History

<b>Received:</b>	January	12-2023
<b>Revision:</b>	February	22-2023
<b>Accepted:</b>	April	20 -2023
<b>Published:</b>	July	05- 2023

### INTRODUCTION

Percutaneous nephrolithotomy (PCNL) currently remains the gold-standard approach for challenging renal stones of the likes of large, complex calculi, complicated or lower pole calculi, stones associated with aberrant renal malformation and failure of other concomitant treatments, and Complexities related to patient's ages, comorbidities, and body habitus. The safety and efficacy of PCNL reveal the unswerving improvements in technology and surgical skills abundantly explained The superseding use of this procedure in the past five decades (1). Standardizing PCNL complications using the modified Clavien-Dindo classification (2) allows comparison of outcomes within a hospital, between different centers, over time, and depending upon the learning curve for other instruments and operating techniques employed. A thorough

review of the recent literature (3) identifies five major developing areas, inspiring prolific innovations in PCNL technique: A. Imaging before, during, and after the procedure; B. Patient positioning (the traditional prone position is now challenged with the emerging supine positions) C. Endoscopy. D. Intracorporeal lithotripsy improved by new devices combining ultrasonic and pneumatic lithotripsy, Trilogi or ultrasonic and high-power holmium: YAG laser lithotripsy); and 5post-PCNL tube care, which includes wholly tubeless an d nephrostomy- free techniques. The surgical management of stones is heavily reliant

## PLACE FOR PERCUTANEOUS NEPHROLITHOTOMY.....

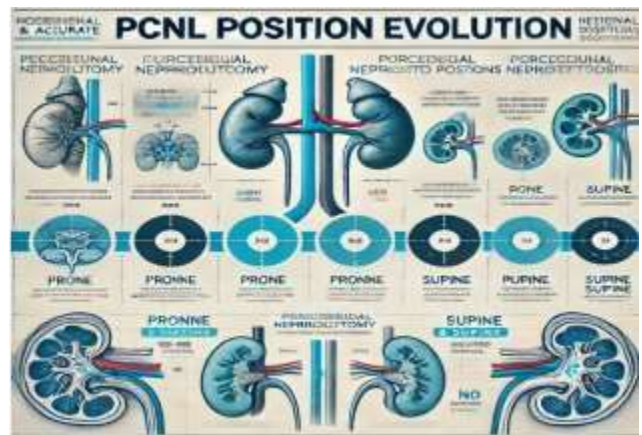
On technology. This holds for the advancement of current tools and technology. Furthermore, robotics and artificial intelligence (4) show great promise and rapidly transform medicine in general and endourology in particular. It's thrilling to imagine a day when an entirely automated, robotically operated, artificially intelligent system would be able to treat patients; this day is not too far off.

## IMAGING

CT scan (5) has authoritatively inscribed on the epitaph of the intravenous urogram, "Rest in peace." It is now moving with diverse innovations like robotic-assisted fluoroscopic-guided and ultrasound-guided renal access in percutaneous nephrolithotomy. The potential benefit of virtual guidance revealed its usefulness both for surgical planning and for surgical Using mixed reality and augmented reality navigation, the goal is to provide the surgeon real-time assistance throughout the intervention. In PCNL, 3D is helpful not only for image reconstruction but also for 3D printing, which has a positive impact on pre- and intraoperative planning by enhancing anatomical spatial comprehension. Compared to routine puncture, An enhanced training experience that translates into a shorter learning curve and a higher stone-free rate is made possible by 3D model printing, virtual and mixed reality, and faster access (6-7). In both supine and prone postures, robotic access increases the puncture accuracy for fluoroscopic and ultrasonography-guided access. Robotics can minimize the necessity for needle punctures, radiation exposure during renal access, and the number of needle punctures by applying artificial intelligence. Integrating robots, virtual and mixed reality, and artificial intelligence can significantly improve PCNL surgery by optimizing every facet of a successful intervention, from entrance to exit (8).

## POSITIONS

It is reasonable to presume that while performing the first percutaneous nephrostomy (Concept given in 1865 & done in 1955), the patient was placed in a prone position primarily to avoid injury to the colon, solid organs, and great vessels (9-10).



## A. SUPINE

Complete Supine, Modified Supine, Oblique Prone, and Supine. Except for a few urologists who sometimes did it in the supine position, it has been done in the same posture for the following forty years. The comparison of supine versus prone PCNL in published literature has not consistently shown a statistically significant advantage for either method in terms of complications or stone-free rates. On the other hand, the supine technique has consistently shown fewer problems and shortened operating times. In conclusion, the surgical team's expertise is crucial when deciding between a supine or prone technique. As a result, it can be concluded that no posture is ultimately better than any other (11-12). It's also crucial to remember that each position in the PCNL method has pros and cons, whether supine or prone. Therefore, while doing PCNL, the posture should be chosen depending on the patient's clinical situation and the surgeon's expertise since the prone position is the norm for PCNL by TRADITION rather than by EVIDENCE (14). The PCNL end-point is dependent on technical precision and is independent of the patient's location. Consequently, urologists must know that PCNL in the supine position is the only option for "difficult patients.(15). Additionally, the supine posture offers a singular chance to integrate all rigid and flexible end urological procedures.

## B. ENDOSCOPY

Since the 1970s, urologists have been able to introduce ureteroscopy and percutaneous nephrolithotomy methods because of advancements in endoscopes and other devices. Subsequent developments included creating endoscopic tools that were more durable and effective. This process never ends since cutting-edge new medical gadgets and tools are constantly being developed. Significant advancements have been made in

## **PLACE FOR PERCUTANEOUS NEPHROLITHOTOMY....**

creating digital camera systems based on complementary metal oxide (CMO) and charge-coupled devices (CCD), as well as the shrinking of equipment.-Superconductor technology(CMOS) (16). These advancements allowed for the construction of flexible ureteroscopy and nephroscope with larger working channels, improved picture clarity, and increased irrigation capacity, all of which facilitated instrument passage. Further developments in digital HD video technology combined with post-processing software such as NBI/SPIES will improve optical field and resolution, enable laser fibers to miniaturize endoscopes and produce more efficient and intelligent irrigation and suction systems (17). Percutaneous nephrolithotomies are now classified into four categories: standard (24–30F), mini (20–22F), ultra/super-mini (12– 14F), and micro (8–10F). Shortly, these gadgets will become more affordable and long-lasting.

## **C. INTRACORPOREAL LITHOTRIPSY**

The energy sources for intracorporeal lithotripsy are as follows: in 1967, electrohydraulic lithotripsy gained popularity; in 1977, ultrasound was used for the first time to destroy renal stones; in 1986, work on developing a laser to fragment ureteral calculi began; and in 1992, the first pneumatic stone fragmentation device was created (18). Renal and ureteral stones are increasingly being treated with laser lithotripsy thanks to advancements in laser fibers and power production devices (19). Numerous commercial brands of thulium fiber lasers and powerful modern Holmium lasers provide many parameters, including pulse width, frequency, and energy. Specific effects of dusting or stone fragmentation may be achieved by varying the combinations of these factors in addition to the laser fiber size and the distance of the fiber tip from the stone (20). More than 15 years ago, the Holmium: Yttrium-Aluminum- Garnet (Ho: YAG) laser was introduced, completely changing the endoscopic treatment of stones (21). Variations of the Thulium Fibre Laser (TFL) are a more recent laser platform with Advantageous physical characteristics in comparison to Ho: YAG (22). Compared to Ho: YAG, which works at a wavelength of 2100 nm, TFL operates at 1940 nm, which is extremely near to the water absorption peak (1950 nm).<sup>11</sup> Thanks to this characteristic, TFL may ablate stones up to four times lower than Ho: YAG while allowing Ho: YAG-like disintegration of all stone kinds. TFL operates across various configurations, producing pulse

energy ranging from 0.025 to 6 J at frequencies as high as 2000 Hz, enabling extremely high peak power (~500 W). Compared to Ho: YAG's bottom limit of 200 µm, TFL's broad range of settings allows it to transfer high-power energy via more minor, more flexible fibers of 50 µm (23–24–25).

## **D-STONE RETRIEVAL DEVICES:**

Removing all stone pieces after lithotripsy has become more critical in endoscopic stone therapy. Because of this, new designs and lower calibers of baskets and graspers are constantly being created. Simultaneously, tools have been developed to remove calculi by hydrodynamic processes (vacuum- cleaner effect, purging, active/passive washout). To stop migration to other calyces and to make extraction easier, small pieces may be added to gels or glue clots (26-27).

## **ROBOTICS:**

The use of robotics in the surgical treatment of prostate and renal cancer is becoming more and more effective. Today, the Da Vinci® surgical system is used all around the globe. With their greater affordability and accessibility, the equipment market has been inundated with newly designed surgical robot systems. In some unique and complicated stone situations, such as simultaneous pyeloplasty–pyelolithotomy, complex pyelolithotomy, and endourological operations, including ureteroscopy and percutaneous nephrolithotomy, these methods have helped to improve the results of minimally invasive treatments (28–29).

## **POST-PCNL TUBE MANAGEMENT.**

Bellman et al. published the first study on tubeless PCNL in 1997 without any significant issues. Limb et al. attempted to define discharge criteria to compare the duration of stay between tubeless and regular PCNL objectively. They listed a variety of variables that may skew this variable, including the healthcare system's policies, the patient's coexisting medical conditions, and the subjectivity of pain perception (30). Aside from stone and patient characteristics, previous research on this subject has shown that these are the most important factors to consider for any PCNL result. The tubeless PCNL group had considerably reduced operational time and a mean hospital stay, as validated by meta-analysis. Nonetheless, there was no difference in the stone-free rate between patients with and without tubes, defined in most trials as residual

## **PLACE FOR PERCUTANEOUS NEPHROLITHOTOMY.....**

pieces < 4 mm and/or no fragment observed on table examination or at initial imaging. Tubeless PCNL had equal or superior results regarding analgesic needs and postoperative discomfort. Maheshwari et al. (31) suggested that patients may be released sooner, have better pain scores, fewer problems, and recover more quickly even with a Standard PCNL if a short pigtail is left in place as a nephrostomy tube. Interestingly, Eslahi et al. (32) also discovered that, compared to regular and tubeless PCNL, the amount of narcotics required and discomfort were much lower in entirely tubeless PCNL (no ureteral stent and no nephrostomy tube). Intraoperative tract infiltration for pain management is becoming a prevalent trend; nevertheless, its efficacy in providing immediate postoperative pain relief and reducing the need for analgesics is unknown. This is particularly true if the patient is evaluated for same-day release (33). As shown by a recent 500-patient research by Chong et al., same-day discharge PCNL is now a reality. They found that 77% of cases had a typical tract dilatation (24–30 Fr), and 99% of cases utilized a ureteral stent as the sole source of drainage. While Tubeless PCNL enabled a quicker surgical procedure, a shorter hospital stay, and a decreased incidence of postoperative Renal cutaneous fistula, per extensive systematic reviews.

## **CONCLUSION**

Advances in the PCNL technique increase stone-free outcomes reduce postoperative complications, an significantly reduce peri-operative patient morbidity. What does the future hold for the benefits due to the use of robotics and augmented reality combined with navigation and motion tracking systems, incorporation of artificial intelligence dedicated efforts for Future developments of radiation-free medical imaging equipment, variation of patient positioning extensive advancement in extracorporeal lithotripsy devices and tubeless percutaneous nephrolithotomy are exhilarating. End urological stone surgery has significantly progressed due to technological advancement over the past two decades. The continued research and development of new instruments and techniques have improved the morbidity and efficiency of the various

lithotripsy modalities. In the future, virtual training and diagnostics will further enhance our ability to treat patients more effectively. Endocrinologists need to keep up to date with the constant updates in methodology and treatment, as it is apparent that the progress and evolution of stone management procedures is an ongoing process far from over. "If doctors were to be found liable whenever they did not effect a cure or whenever something happened to go wrong, it would be a great disservice not only to the profession itself but to society at large."

## **SUMMARY:**

The standard gold medical procedure for complex renal stone treatment is percutaneous nephrolithotomy (PCNL) because technological advancements alongside surgical techniques refined its effectiveness. Significant improvements in patient outcomes result from modern innovations including imaging technologies together with improvements in patient positioning systems and endoscopy tools and lithotripsy devices and care for patients after PCNL. PCNL's future development has promise through new technologies including robotics along with artificial intelligence and augmented reality that will improve both precision and lessen complications in urological surgery.

**Acknowledgment:** Thank you to the hospital management and everyone who helped us finish the study.

**Disclaimer:** Nil

**Conflict of Interest:** There is no conflict of interest.

**Funding Disclosure:** Nil

### **Authors Contribution**

**Concept & Design of Study:** Abdul Majid Rana

**Drafting:** Abdul Majid Rana

**Data Analysis:** Abdul Majid Rana

**Critical Review:** Abdul Majid Rana

**Final Approval of version:** Author Have Reviewed And Approved The Final Manuscript.

## REFERENCES.

1. Elisa De Lorenzis, Stefano Paolo Zanetti, Luca Boeri, Emanuele Montanari. Is There Still a Place for Percutaneous Nephrolithotomy in Current Times? *J ClinMed* 2022 Aug 31; 11(17):5157
2. D. Dindo, N. Demartines, and P.-A. Clavien, "Classification of surgical complications: a new proposal with evaluation in a cohort of 6336 patients and results of a survey," *Annals of Surgery*, vol. 240, no. 2, pp. 205–213, 2014.
3. Cecilia M. Cracco, Cesare M. Scoffone, and Roberto M. Scarpa "New developments in percutaneous techniques for simple and complex branched renal stones' *Current Opinion in Urology* 2017, Mar;21(2):154-60
4. Vineet Gauhar et al., An Update of in Vivo Application of Artificial Intelligence and Robotics for Percutaneous Nephrolithotripsy: Results from a Systematic Review; *Curr Urol Rep*, 2023 Jun; 24(6):271-280.
5. Ghani KR, Patel U, Anson K. Computed tomography for percutaneous renal access. *J Endourol* 2009; 23:1633–1639.
6. Shah M, Naik N, Somani BK, Hameed BMZ. Artificial intelligence (AI) in urology-current use and future directions: an iTRUE study. *Turk J Urol*. 2020; 46(Supp. 1):S27–S39.
7. Xu Y, Yuan Y, Cai Y, Li X, Wan S, Xu G. Use 3D printing technology to enhance stone-free rate in single tract percutaneous nephrolithotomy to treat staghorn stones. *Urolithiasis*. 2020; 48(6):509–516.
8. Taguchi K, Hamamoto S, Okada A, Sugino T, Unno R, Kato T, Fukuta H, Ando R, Kawai N, Tan YK, Yasui T. A Randomized, Single-Blind Clinical Trial Comparing Robotic-Assisted Fluoroscopic-Guided with Ultrasound-Ultrasound-guided renal Access for Percutaneous Nephrolithotomy. *J Urol*. 2022 Sep; 208(3):684–694.
9. Goodwin WE, Casey WC, Woolf W. Percutaneous trocar (needle) nephrostomy in hydronephrosis *JAMA* 1955;157:891-4.
10. Zhijian Zhao · Junhong Fan · Yang Liu · Jean de la Rosette · Guohua Zeng. Percutaneous nephrolithotomy: position, position, position, *Urolithiasis* (2018) 46:79–86
11. Roshan M. Patel, Zhamshid Okhunov, Ralph V. Clayman, Jaime Landman; Prone Versus Supine Percutaneous Nephrolithotomy: What Is Your Position? *Curr Urol Rep*. 2017 Apr; 18(4):26. Review. PMID: 28247328 (16 studies)
12. David K-C.Mak, Yuko Smith, Noor Buchholz and Tamer El Hussein; what is better in percutaneous nephrolithotomy – Prone or supine? A systematic review *Arab J Urol*. 2016 March 04; 14(2):101-7. Review.PMID: 27489736 (30 Studies)
13. EAU Guidelines.Presented at the EAU Annual Congress Amsterdam. 2022.978-94-92671- 16-5. Available online:
14. Rana A.M., Bhojwani JP, Junejo NN and Das Bhagia S. Tubeless PCNL in Supine! Procedure for all seasons? With comprehensive technique. *Urology*; 2018 Apr; 71(4):581-5.
15. Valdivia Uría JG, Valle Gerhold J, López López JA, Villarroja Rodriguez S, Ambroj Navarro C, Ramirez Fabián M et al. Technique and complications of percutaneous nephroscopy: experience with 557 patients in the supine position. *J Urol* 1998; 160:1975-8.
16. A. Rodgers· A. Trinchieri· M. H. Ather · N. Buchholz. *Urolithiasis* (2019) 47(5):401–413 Vision for the future on Urolithiasis: research, management, education, and training—some personal views.Lahme S. Miniaturisation of PCNL. *Urolithiasis*.2018 Feb; 46(1):99-106.
17. Patil A., Sharma R., Shah D., Gupta A., Singh A., Ganpule A., Sabnis R., Desai M. A prospective comparative study of mini-PCNL using Trilogy or thulium fiber laser with suction. *World J. Urol*.2022 Feb; 40(2):539- 543.
18. Kronenberg P, Somani B. Advances in lasers for treating stones—a systematic review. *Curr Urol Rep* 2018 May 17; 19(6):45.
19. Tzelves L, Somani B, Berdempes M, Markopoulos T, Skolarikos A. Basic and

## PLACE FOR PERCUTANEOUS NEPHROLITHOTOMY.....

advanced technological evolution of laser lithotripsy over the past decade: An educational review by the European Society of Agrotechnology section of the European Association of Urology. *Turk J Urol.* 2021; 47(3):183–192.

20. Black KM, Aldoukhi AH, Ghani KR. A user's guide to holmium laser lithotripsy settings in the modern era. *Front Surg.* 2019 August 14; 6:48.

21. Traxer O, Keller EX. Thulium fiber laser: the new player for kidney stone treatment? A comparison with holmium: YAG laser. *World J Urol* 2020 Aug; 38(8):1883-1894.

22. Jones P, Beisland C, Ulvik Ø. Current status of thulium fiber laser lithotripsy: an up-to-date review. *BJU Int.* 2021; 128(5):531–538.

23. Korolev D et al. Minimally invasive percutaneous nephrolithotomy with Super Pulsed Thulium-fibre laser. *Urolithiasis.* 2021; 49:485–491

24. Basulto-Martínez M, Proietti S, Pavia MP, Yeow Y, Eisner BH, Giusti G. Understanding the ablation rate of holmium: YAG and thulium fiber lasers. Perspectives from an in vitro study. *Urolithiasis.* 2023; 51(1):32.

25. Cloutier J, Cordeiro ER, Kamphuis GM, Villa L, Letendre J, de la Rosette JJ, Traxer O. The glue-clot technique: a new technique Description for small calyceal stone fragments removal. *Urolithiasis* 42:441–444

26. Zanetti S.P., Lievore E., Fontana M., Turetti M., Gallipoli A., Longo F., Albo G., De Lorenzis E., Montanari E. Vacuum-assisted mini-percutaneous nephrolithotomy: A new perspective in fragments clearance and intrarenal pressure control. *World J. Urol.* 2021; 39:1717–1723

27. Siddiqui KM, Albala DM (2016) Robotic-assisted surgery and treatment of Urolithiasis. *Int J Surg* 36:673–675

28. Vineet Gauhar et al., An Update of in Vivo Application of Artificial Intelligence and Robotics for Percutaneous Nephrolithotripsy: Results from a Systematic Review; *Curr Urol Rep*: 2023 Jun; 24(6):271-280.

29. Rana A.M. Mithani S. Tubeless Percutaneous Nephrolithotomy; Call of the Day. *J Endourol* 2007; 21, 169-172.

30. Maheshwari PN, Andankar MG, Bansal M. Nephrostomy tube after percutaneous nephrolithotomy: large-bore or pigtail catheter? *J Endourol.* 2000;14:735–738

31. Eslahi A, Irani D, Hosseini MM, Safarpour AR. Tubeless percutaneous nephrolithotomy: a comparison with tubeless and standard methods. *Nephrourol Mon.* 2017; 9

32. Chong JT, Dunne M, Magnan B, et al. Ambulatory percutaneous nephrolithotomy in a free-standing surgery center: an analysis of 500 consecutive cases. *J Endourol.* 2021; 35:1738–1742.



### Licensing and Copyright Statement

All articles published in the *Pakistan Journal of Urology* are licensed under the terms of the **Creative Commons Attribution 4.0 International License (CC BY 4.0)**

This license allows users to **share** (copy and redistribute) and **adapt** (remix, transform, and build upon) the published material for **any purpose, including commercial**, provided appropriate credit is given to the original author(s) and the source (*Pakistan Journal of Urology*), a link to the license is provided, and any changes made are indicated.

[This work is licensed under a Creative Commons Attribution 4.0 International License.](#) © The Author(s) 2023