

## A CASE REPORT

## Recurrent Para -Testicular Rhabdomyosarcoma A Case Report

Sana Hamayun<sup>1</sup>, Wagma Hidayat<sup>2</sup>, Hamza Rafi<sup>3</sup>, Haq Nawaz<sup>4</sup><sup>1,2,3,4</sup> Department Of General Surgery, Hayatabad Medical Complex, Peshawar, Pakistan.

## ABSTRACT

**Background:** Para-testicular RMS is not frequently reported and originates from the stromal tissues of the spermatic cord, epididymis, testis and tunica. It is a very uncommon feature in RMS and may be seen in a small percentage of patients and most often in children. At times the diagnosis may pose as a problem and physical examination may be inadequate at which time ultrasonography comes in handy. The main form of management is surgical through radical orchiectomy and the medical form is through Actinomycin D, vincristine and cyclophosphamide and very rarely radiotherapy.

**Keywords:** Para-Testicular Rhabdomyosarcoma, Radical Orchiectomy, Chemotherapy, Ultrasonography

## Introduction:

Para-testicular RMS spermatic cord, epididymis, testis, and tunica vaginalis. It is noted in 7 % of all patients in IRS and accounts for 17% of all malignant intrascrotal tumours in children less than fifteen years of age [1]. Alveolar; Embryonal; Botryoid embryonal; Spindle cell embryonal; Anaplastic. These are according to the international RMS classification. rRMS is the most frequent variant, encompassing 60% of cases; it is also known as embryonal RMS (eRMS). Para-testicular rhabdomyosarcoma is often associated with rather vague clinical symptoms. The diagnostic procedures are – ultrasonography (US), which is used to identify the tumor localization if it cannot be determined by physical examination [2]. For histological diagnosis and the initial treatment, the initial surgical procedure is radical orchiectomy through the inguinal route, ligated initially irrespective of the disease state. Like most adult soft tissue sarcomas, rhabdomyosarcoma is chemosensitive; this is why chemotherapy forms a section of the treatment regimen; typical drugs are Actinomycin D, vincristine and cyclophosphamide. Radiotherapy is also sometimes incorporated in this treatment [3].

**How to Cite :** Hamayun, S., Hidayat, W., Rafi, H., & Nawaz, H. Recurrent Para-Testicular Rhabdomyosarcoma: A Case Report. Pak J Urol.2024;2(01), 110–113. <https://doi.org/10.69885/pju.v2i01.65>

Corresponding Author: Wagma Hidayat

Department of General Surgery, Hayatabad medical complex Peshawar

Email: [dr.wagmahidayat707@gmail.com](mailto:dr.wagmahidayat707@gmail.com)

<https://orcid.org/0009-0008-6760-9570>

Cell no: +92-313-9636549

## Article History

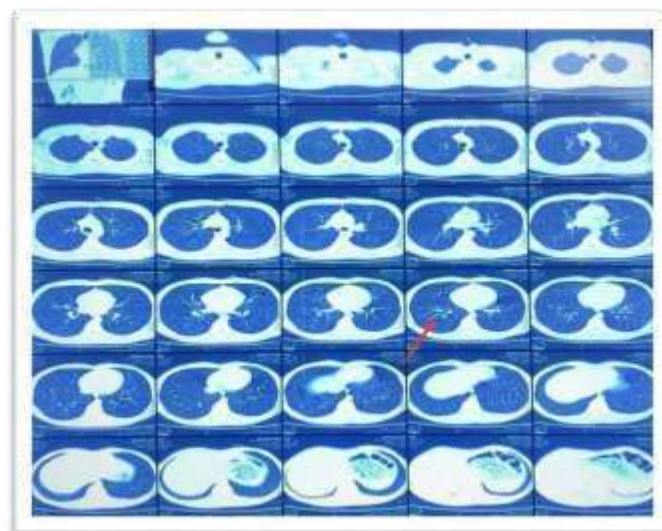
Received:	January	20-2024
Revision:	February	16-2024
Accepted:	April	22-2024
Published:	July	05- 2024

## CASE PRESENTATION:

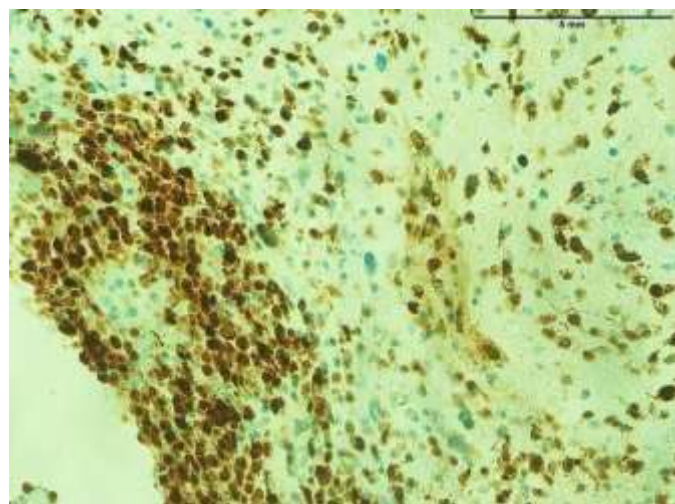
16-year-old boy presented in Surgical OPD with swelling in the right inguinal region of one months duration, who had right radical orchiectomy done one year back for scrotal mass biopsy revealed embryonal rhabdomyosarcoma of para testicular origin while testes and speramtic cord were negative for tumor. He had completed adjuvant chemo-therapy of six cycles of VCR 2 gm, CTX 1 gm and DOX 90 mg. There we saw the scar at the operation site in the right inguinal area and a hard irregular rubbery immobile mass which extended up to the scrotum. Ophthalmoscopy examination was also unproductive; trans illumination test was also negative. Routine investigations were normal and so was the liver function whereas, tumor markers including LDH, alpha-fetoprotein and beta-HCG were well within normal range. On the abdominal ultrasound there was a lobulated mass of size 5x9 cm in the right inguinal region that had micro-calcification. On the abdomen and pelvic CT scan, a deforming mass of size 10cm X 6 cm was observed in the right inguinal region with fat stranding and enlarged nodes were also noted and multiple indeterminate pulmonary nodules were also observed (Fig 1 & 2). A tru-cut biopsy was performed and immune staining with desmin and myo-D was positive as shown in figures 3 and 4 and the diagnosis of recurrent embryonic rhabdomyosarcoma was made and confirmation was sought from other pathologists. A preoperative patient was on the stage. In course of surgery, a massive necrotic area was seen involving the adductor muscles and the lymph nodes above and below the oblique abdominal muscle; the scrotum was also found to have necrosis. The mass was felt to be misconceived as non-respectable and consequently debunking was done (Figure 5). The specimen was finally subjected to histopathology as the one depicted in the figure 6. He was subsequently referred to a medical oncologist for assessment and management of the case.



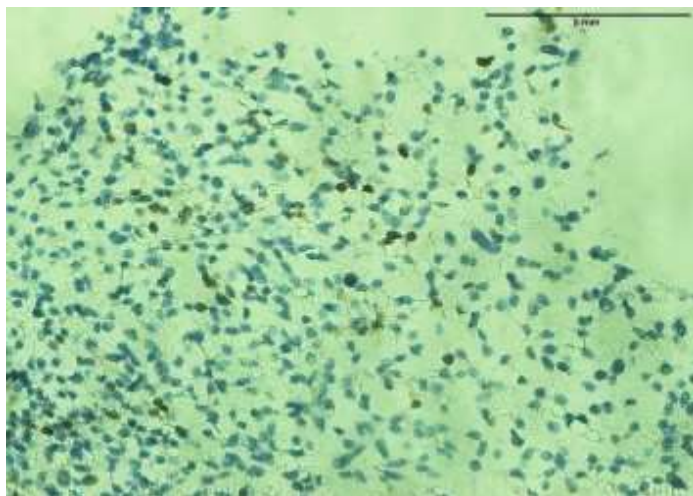
**Figure 1: Ct Abdomen Pelvis Shows A Large Right Inguinal Region Mass As Pointed By The Red Arrow**



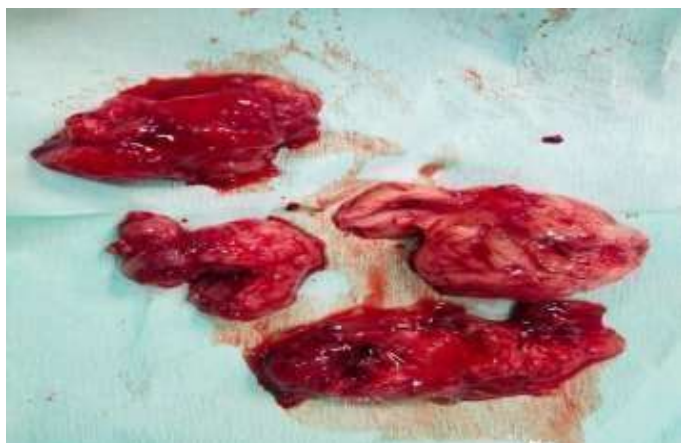**Figure 2: Ct Chest Shows Some Indeterminate Pulmonary Infiltrates As Pointed By The Red Arrows**



**Figure 03: Indeterminate Pulmonary Infiltrates  
As Pointed By The Red Arrows**



**Figure 4: Desmin Positive and Myogenin D Positive**



**Figure 5: Debulk Tissues Of The Tumour**

## DISCUSSION

Alveolar rhabdomyosarcoma (RMS) serves from embryonal mesenchymal and is one of the most malignant tumors [4]. It has four subtypes: These are embryonal, alveolar, pleomorphic and spindle cell. RMS typically arises from soft tissues and affects mainly the head and neck, ocular and orbital region, GU tract and genitals, and limbs [5]. Testicular RMS is also known as para – testicular RMS and is the seventh most prevalent RMS responsible for 7% of all RMS; it is a rather rare tumor that develops from spermatocytes cells of epididymal and spermatic cord origin [6]. This tumor is seen in children and young adults and therefore the age distribution is bimodal with age of 5 and 16 respectively as in the above case.

Depending on the stage of development and it is the most common; the disease can be cured if identified in its early stage. Nevertheless, the relapse rate is quite high, and in our patient, recurrent bilateral pulmonary nodules were diagnosed one year after right orchiectomy. Most para-testicular tumors are found incidentally and are painless mass in the scrotum at the time of presentation, they have often spread hematogenously to iliac and par aortic lymph nodes or lungs and bones [7]. The edema is asymptomatic and so patients do not seek medical help and end up presenting at the advanced stage of the disease. The manoeuvres that should be included are the scrotal palpation, inguinal lymph node, other lymph node, general physical examination and the systemic examination for metastasis [8]. Para-testicular RMS is amongst the causes of scrotal swellings and treatment with inguino-scrotal ultrasound is useful in differentiating it from other conditions due to the demonstration of the lobulated heterogeneous mass that characterizes this tumor vulgaris. Tumor marker assays that are normally elevated in testicular swellings are usually normal in para-testicular RMS although there may be a slight rise in the LDH [9]. For staging of disease and to check loco-regional invasion or metastasis, Thoraco- Abdominal-Pelvic CT and MRI are the gold standard. All these imaging techniques assist in planning the treatment. Treatment of para-testicular RMS should consist of surgery – radical, retroperitoneal lymph node dissection, radiotherapy and chemotherapy [10,11]. In radical orchiectomy essential histological information is obtained and this is the first operation carried out. This is then followed by chemotherapy, which normally takes 4-6 cycles of a program such as Vincristine, Cyclophosphamide and Adriamycin (VAC), which is known to be effective. Regional lymph node and metastatic disease is mainly treated by radiotherapy. For the children affected by the para-testicular RMS the prognosis is comparatively better than that of the adults, therefore, early diagnosis and multifaceted treatment is advisable [12]. Such patients therefore require follow up and regular evaluation, in order to note the re occurrences and any consequent effects. It becomes important to rise the level of attention and to detect the disease in its early stages to improve the prognosis and survival rate of the para-testicular RMS patients [13].

## CONCLUSION

We suspect that the diagnosis of para testicular RMS is not straightforward in many cases and ultrasonography becomes particularly beneficial if physical examination only is inconclusive. The management consists of the surgical treatment that is the removal of the tumor with the affected testicle, orchiectomy; the chemotherapeutic treatment usually Actinomycin D, vincristine, cyclophosphamide and the use of radiotherapy in some special cases.

## REFERENCES

1. Abdelazim YA, Zaki MF, Abdel Mohsen MM, Emad RM, Mohamad HG, Abdelfatah D, et al. Treatment results of Para-Testicular Rhabdomyosarcoma (PT-RMS) using radiation as an alternative to retro-peritoneal nodal dissection: A single Institution experience. *Archivio italiano di urologia, andrologia : organo ufficiale [di] Societa italiana di ecografia urologica e nefrologica*. 2023;95(4):11642.
2. Ashuvanth S, Sinduja R, Vijayakumar C, Kumbhar U, Toi PC. Testicular Torsion in a Rare Case of Prostatic Spindle Cell Rhabdomyosarcoma. *Cureus*. 2020;12(12):e12238.
3. Bernaschina-Rivera CI, Bernaschina-Bobadilla CP, Gutierrez-Rivera S. Report of a Primary Testicular Embryonal Rhabdomyosarcoma. *Puerto Rico health sciences journal*. 2022;41(4):250-3.
4. Ghazanfar NA, Anwar MS, Shah AA, Saeed H, Kashif M. Adult Para Testicular Spindle Cell Rhabdomyosarcoma: A Case Report From Pakistan. *Cureus*. 2023;15(12):e50082.
5. Guo CC, Czerniak B. Somatic-type malignancies in testicular germ cell tumors. *Human pathology*. 2022;127:123-35.
6. Guo CC, Czerniak B. Reprint of: somatic-type malignancies in testicular germ cell tumors. *Human pathology*. 2023;133:102-14.
7. Ihssan E, Salma E, Ayoub M, Amine S, Zakia B, Kaoutar Z. Primary intra-testicular rhabdomyosarcoma: Case report. *International journal of surgery case reports*. 2022;96:107340.

**Disclaimer:** Nil

**Conflict of Interest:** Nil

**Funding Disclosure:** Nil

### Authors Contributions

**Concept & Design of Study:** Sana Hamayun

**Drafting:** Wagma Hidayat

**Data Analysis:** Hamza Rafi

**Critical Review:** Haq Nawaz

**Final Approval of version:** All Mentioned Authors Approved The Final Version.

8. Sammour M, Altheneyan M, Almarzouq Y, Almulhim A, Alhazzani N. Testicular non-seminomatous mixed germ cell tumor with rhabdomyosarcoma and retroperitoneal metastatic mass: A case report. *Urology case reports*. 2021;34:101475.
9. Su P, Yang Y, Wang X, Chen S, Zhang N, Yang H. A case report of primary para-testicular spindle cell rhabdomyosarcoma. *Frontiers in oncology*. 2023;13:1166503.
10. Urgun DA, Bista B, Krishnam M. Unusual presentation of testicular rhabdomyosarcoma metastases to the right ventricle papillary muscle and tricuspid valve. *Radiology case reports*. 2020;15(9):1562-5.
11. Xu X, Liu Z, Li Y, Fan L, Wang S, Guo J, et al. Single Nuclear RNA Sequencing Highlights Intra-Tumoral Heterogeneity and Tumor Microenvironment Complexity in Testicular Embryonic Rhabdomyosarcoma. *Journal of inflammation research*. 2022;15:493-507.
12. Yahaya JJ, Mremi A. Primary intratesticular rhabdomyosarcoma in children: a case report and review of the literature. *Journal of medical case reports*. 2021;15(1):37.
13. Ye JF, Zhao L, Wang GL, Hong K, Ma LL. [Clinical analysis of testicular rhabdomyosarcoma]. *Beijing da xue xue bao Yi xue ban = Journal of Peking University Health sciences*. 2021;53(6):1178-82.



### Licensing and Copyright Statement

All articles published in the **Pakistan Journal of Urology** are licensed under the terms of the **Creative Commons Attribution 4.0 International License (CC BY 4.0)**. This license allows users to share (copy and redistribute) and adapt (remix, transform, and build upon) the published material for any purpose, including commercial, provided appropriate credit is given to the original author(s) and the source (**Pakistan Journal of Urology**), link to the license is provided, and any changes made are indicated. **This work is licensed under a Link: [Creative Commons Attribution 4.0 International License](https://creativecommons.org/licenses/by/4.0/). © The Author(s) 2024.**

**Publisher:** Institute of Kidney Diseases and Pakistan Association of Urological Surgeons (PAUS)